

CENTRAL ARIZONA MEDICAL ASSOCIATES, P.C.

Gastroenterology

David B. Leff, D.O.
Michael B. Seip, D.O.
Richard Jonas, M.D.

Internal Medicine

Joe K. Gregory, D.O.
Jack D. Butler, D.O.

Pulmonary Medicine

William S. Dishner, D.O.
George C. Parides, D.O.

December 12, 2002

Richard A. Melde, M.D.
2222 S. Dobson Road, #1100
Mesa, AZ 85202-6201

Re: Earl W. Herr
DOB 12/12/1962

Dear Dr. Melde,

I saw Mr. Herr in the office today for a complaint of some abdominal pain.

SUBJECTIVELY: He states he has had influenza recently and has had coughing paroxysms. He coughs so much that he started to develop abdominal pain and experienced severe pain in the region of his biliary tract surgery. He had some problems with a bile leak and also had pancreatitis following an ERCP where a stent was placed. He seems to have no severe pain today. There is perhaps some soreness.

OBJECTIVELY: On physical examination today, I find a 39-year-old male who has gained some weight since his last visit. In fact, it would appear he has gained 25 lbs. Blood pressure 138/100. Abdomen shows scars from his recent surgery. He has normal bowel sounds. We find no peritoneal signs at all. There does not really seem to be any tenderness on palpation at all.

PLAN: I have told him that he could expect to have some tenderness due to the abdominal adhesions, which would have developed following surgery and any irritation from a bile leak. Unfortunately, these will be present the rest of his life, and the only way to remove them would be surgery, but in his case, I advised him to avoid surgery at all costs.

Thank you very much for allowing me to participate in the care of your patient.

Sincerely,



Michael B. Seip, D.O.

MBS/dlm

Dictated but not read

334 W. 10th Pl., #100
Mesa, Arizona 85201
(480) 834-0771

6550 E. Broadway Rd., #201
Mesa, Arizona 85206
(480) 324-0999

19841 N. 27th Ave., #203
Phoenix, Arizona 85027-4001
(602) 279-9848

Patient: Herr, Earl W. - 1819402
Procedure: ERC
Doctor: Seip, Michael
Facility: Valley Lutheran Medical Center

Date: 05/17/2002
Time: 8:12am

Image 1

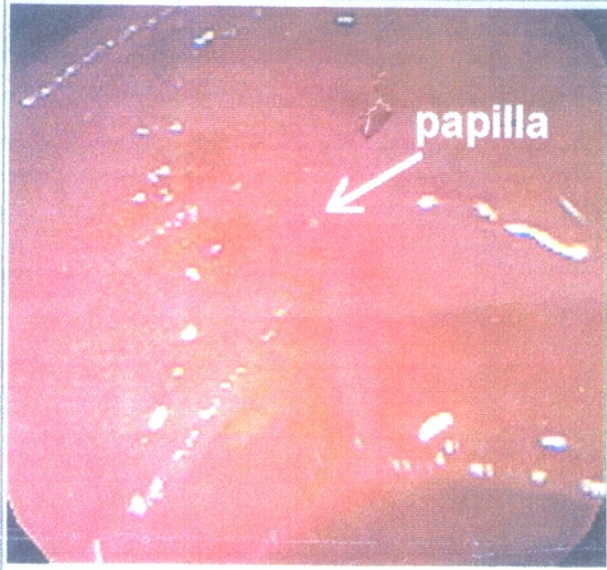


Image 2

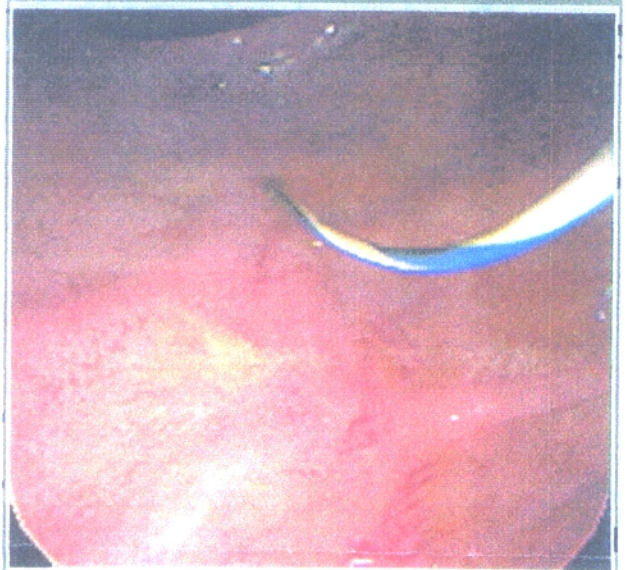
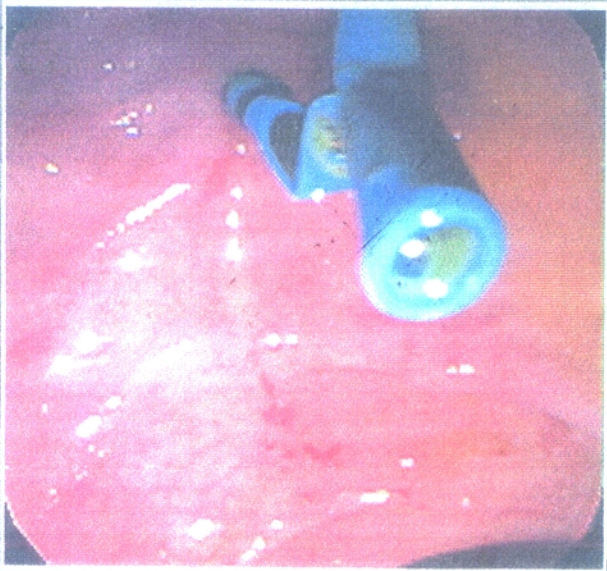


Image 3



ERCP2

